

## ACUTE MYOCARDITIS IN RATS INOCULATED WITH *TRYPANOSOMA CRUZI*: STUDY OF ANIMALS SACRIFICED BETWEEN THE FOURTH AND TWENTY-NINTH DAY AFTER INFECTION

Cecilia SCORZA and J. V. SCORZA

### SUMMARY

The myocardial lesions found in 56 female Wistar 40 days old white rats inoculated with the blood forms of the "Y" strain of *Trypanosoma cruzi* are described. The course of parasitaemia in certain of the animals is followed and compared with the myocardial changes in the acute phase. The study of the animals at different periods after inoculation permits the establishment of the similarity of the myocardial lesions in these animals to those described in the experimental material of other investigators and in human material. The most significant process is the ganglionitis and periganglionitis of the subepicardial parasymphathetic ganglia, with irreversible destruction of groups of neurons. The relationships between these alterations and the intensity of the acute inflammatory process is discussed.

### INTRODUCTION

An extensive review of the literature has suggested that an appropriate host-parasite system for the study of the histopathology of the myocardium in acute experimental chagasosis would be the white rat (*Rattus norvegicus*) infected with the "Y" strain of *Trypanosoma cruzi* (SILVA & NUSSENZWEIG)<sup>16</sup>. The results to be given in the present preliminary report appear to confirm this, and the advantages of this host-parasite system are discussed later, comparing results with those of other investigators of the same problem.

### MATERIALS AND METHODS

Eighty-eight female Wistar white rats, approximately 40 days old, were used. They were separated into three groups: 32 rats inoculated intraperitoneally with approximately 50,000 parasites apiece; 24 rats inoculated with 200,000 parasites; and a con-

trol group of 32 rats. The parasites were the stout trypomastigotes of the "Y" strain of *Trypanosoma cruzi*, taken from white mice that had been infected for 25 days; they were counted by the technique of BRENER<sup>3</sup>.

The animals were kept in groups of 10 or 12 in cages 60 X 40 X 20 cm, at 22°C and 60% relative humidity, with a photoperiod of 12 hours; water and commercial laboratory diet were given *ad libitem*. To follow the parasitaemia, periodic counts were made on three rats of the first experimental group, taking 10 microliters of blood from the tail for each count, according to the technique of BRENER<sup>3</sup>.

On the 4th, 8th, 11th, 14th, 18th 21st, 25th, and 29th day after infection, 4 animals from the first experimental group, 3 from the second, and 4 from the control group were sacrificed by cervical dislocation on Nembutal anesthesia. The thorax was immediately opened and the heart, together with the attached large vessels, was taken out. The

organ was frozen in Arcton 22 and maintained at  $-70^{\circ}\text{C}$ . Within 24 hours after extraction, serial frontal sections of 6-8 micra were made with a SLEE-Pearse cryostat; the sections were placed on coverslips.

Sections were fixed in various ways. Those fixed with anhydrous acetone at room temperature were stained with Gomori or Harris haematoxylin plus eosin. Those fixed for one hour at room temperature with formalcalcium were stained with Van Gieson. Others, fixed for 5 minutes with saline formal were stained with "Oil Red" according to LILLIE<sup>10</sup>; with Sudan Black according to LISON & DAGUELIE<sup>11</sup>, modified by BANCROFT<sup>2</sup>; or — for secondary fluorescence — with aqueous Fosfina 3 R according to PEARSE<sup>12</sup>. Finally, sections fixed for 60 minutes with 1% celloidin in absolute alcohol were stained by PAS technic.

## RESULTS

Parasitaemia was observed in three rats that had been inoculated with 50,000 trypanosomes apiece. No counts were made on animals infected with 200,000 parasites. Parasitaemia with low numbers of trypanosomes were seen to increase after the eighth day, with crisis between the tenth and eleventh day leading to progressively lower values until the conclusion of observations on the 29th day.

Since histological examinations showed no significant differences in heart pathology between animals infected with 50,000 and 200,000 parasites, nor were any other phenomena appreciably different between the two groups, the following descriptions are based on the observations made indifferently on the seven animals from the two groups sacrificed at each interval.

*4 days after infection* — No parasites were seen, nor were any alterations observed in the structures of the heart, the great vessels, or the neurons of the subepicardial parasymphathetic ganglia.

*8 days after infection* — Pseudocysts were seen, more abundant in the right auricle and in the walls of the common vena cava; a few nests in the ventricles, predominantly in the

base of the right ventricle. The number of pseudocysts was always somewhat larger in the animals inoculated with the larger number of parasites. Neither diffuse inflammation around the nests, nor vasculitis, nor neuronal changes were observed.

*11 days after infection* — Increase in the number of pseudocysts, with the same tendency to concentrate in the right auricle and the walls of the veins of the cardiac hilum. The majority of the nests appeared to be intact, without inflammatory reaction; some pseudocysts were ruptured, with free leishmanoids in the interstitial tissue; these appeared to be surrounded by intense inflammatory infiltration, consisting of macrophages, lymphocytes, monocytes, and polymorphonuclear leucocytes; many of the macrophages appeared to contain phagocytized parasites. The inflammatory infiltration appeared diffuse in certain areas, apparently without relation to the presence of parasites; there was intense capillary dilation, together with ganglionitis and subepicardial periganglionitis (Fig. 1). In certain animals of the second experimental group, there was inflammatory infiltration of His' bundle, the fibers of which were dissociated by the oedema and the infiltration.

*14 days after infection* — Intense acute diffuse myocarditis of phlegmatic aspect, together with pericarditis and endocarditis. The inflammation and the oedema were greater in the auricles than in the ventricles. Most of the nests were ruptured and parasites seen free or phagocitized by macrophages (Fig. 2), which now became abundant. Vasculitis was observed, as was the presence of mast cells, some liberating granules. In the auricles, the oedema was so intense that the myocardial fibers appeared dissociated and slender. Intense ganglionitis and subepicardial periganglionitis was seen, and some neurons showed chromatolysis and vacuolar degeneration. Pseudocysts were present in the capsular cells.

*18 days after infection* — No parasites were observed in any of the sections. There was intense diffuse myocarditis, epicarditis, endocarditis. In some vessels, oedema of the walls and vasculitis were seen. The in-

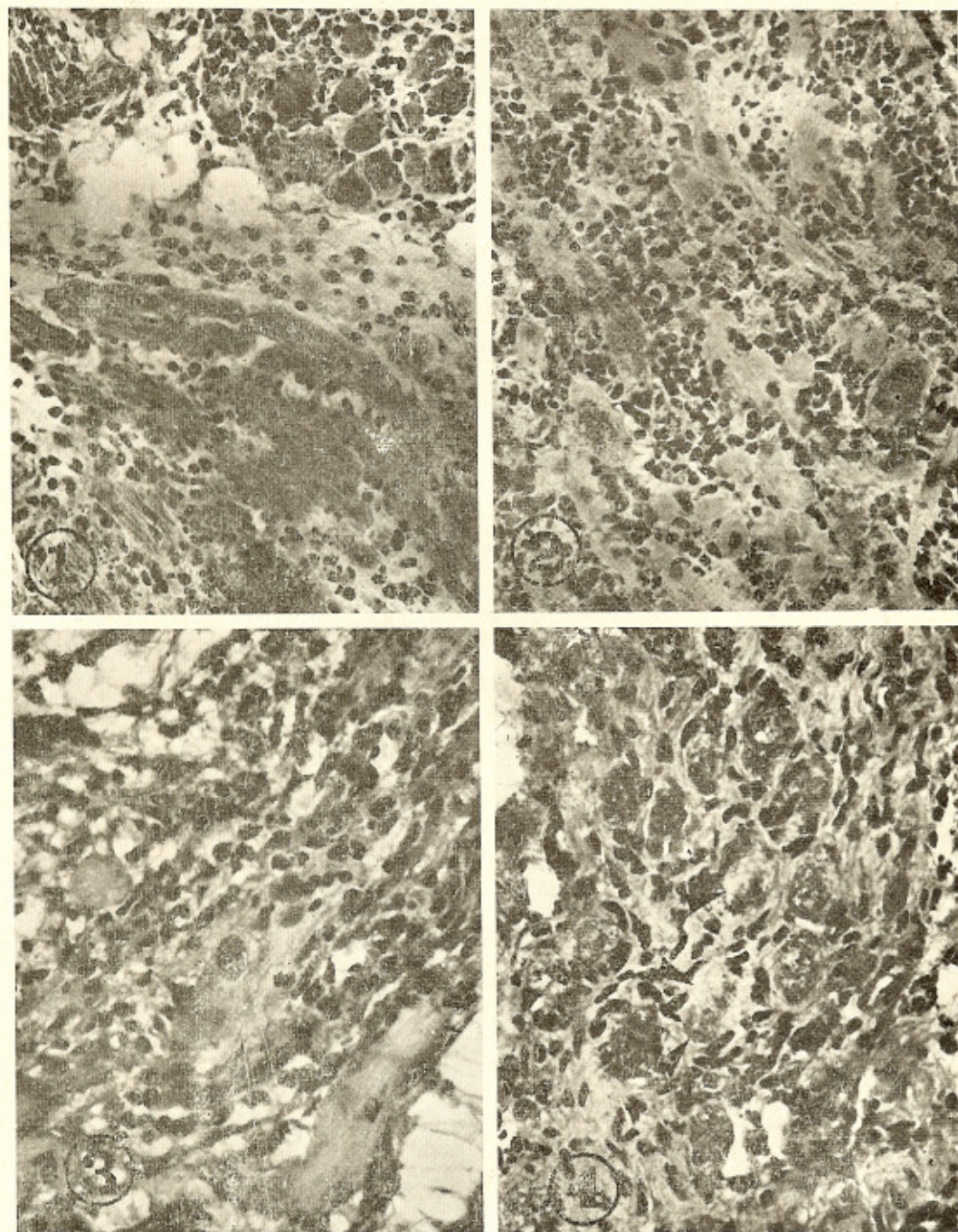


Fig. 1 — Subepicardial ganglionitis in 11th days infected rat. Haematoxylin-Eosin, 258  $\times$ . Fig. 2 — Acute diffuse myocarditis in rat 14 days after inoculation; ruptured nests of parasites altogether with free and phagocytized parasites are seen. H.E., 258  $\times$ . Fig. 3 — Cardiac fibers phagocytized by macrophages in rat 14 days after infection with *T. cruzi*. H.E., 381  $\times$ . Fig. 4 — Subepicardial ganglion; some neurons (arrows) showing chromatolysis in rat heart 21 days after inoculation. H.E., 381  $\times$ .

flammatory infiltration was predominantly histioplasmocytic, being far more intense in the auricles and in the walls of the vessels of the hilum. Interstitial oedema was diminished. Some muscle fibers were seen to be fragmented and in the process of being phagocytized (Fig. 3) in certain areas, remnants of fibers with hypertrophied nuclei were seen. There was ganglionitis and subepicardial periganglionitis. Chromatolysis and vacuolar degeneration were seen in some neurons.

*21 days after infection* — The sections were very similar in appearance to those from the 16th day. The diffuse inflammatory process had continued but the oedema had diminished. Chromatolysis was observed in some neurons (Fig. 4). No parasites were seen.

*25 days after infection* — Oedema and vasculitis had disappeared. The inflammatory infiltration had largely disappeared leaving only foci in the auricles and in the walls of the great vessels of the hilum; there were very few foci in the ventricles. In one of the animals of the first experimental group, there was a marked dilation of the common vena cava, whose walls appeared thinned, together with inflammatory infiltration. A parasympathetic ganglion in the vicinity showed atrophied neurons. There was also a great dilation of the ventricular subepicardial venules and capillaries, and also discrete arteritis. No parasites were seen.

*29 days after infection* — Lymphocytic foci were observed in the auricles; these were very scarce in the ventricles. There was no oedema and the vascular process had completely disappeared. Groups of atrophied myocardial fibers and discrete hyperplasia of the connective tissue were observed toward the bases of the ventricles. Chromatolysis persisted in groups of neurons. No parasites were observed.

Fatty degeneration of the fibers was not seen in any of the hearts of any of the sacrificed animals, nor was it possible to find any fat reaction in any of the parasites.

Nothing of pathological interest was found in any of the control animals sacrificed.

## DISCUSSION

The susceptibility of albino *Rattus norvegicus* to infection by *T. cruzi* was studied by DIAS<sup>4</sup>; this Author considered the animal a suitable subject for the study of acute and chronic infections. KOLODNY<sup>8</sup> found that 10 days old white rats perished 18 days after infection, although the apparent number of parasites was low. PIZZI et al.<sup>13</sup> studied *T. cruzi* infections in white rats of either more or less than 100 days of age, without recording any mortality whatever; they reported a bimodal course of the parasitaemia with two separate crisis in 80% of the animals. These results were later confirmed by PIZZI & CHEMKE<sup>15</sup>. Animals 30 days old, according to VICHI<sup>20, 21</sup>, die during the acute phase of the parasitaemia, 16-22 days after inoculation with approximately 150,000 parasites, GOMEZ DE ALCANTARA<sup>5</sup> had obtained similar results, reporting 60% mortality within 16 and 25 days after inoculation in animals 19 and 25 days of age. The remaining animals survived up to 8 months.

The results of the present experiments partially confirm those of PIZZI et al.<sup>13</sup>; 56 rats of 40 days of age were inoculated, but no deaths occurred in the animals until the last were sacrificed.

Although all the animals were examined between the 4th and 8th days after inoculation to establish the presence of the parasites, the course of the parasitaemia was followed in only three of the experimental animals. These showed a single peak of the parasitaemia between 8 and 10 days after the inoculation, followed by a crisis, after which no more than 2-4 trypanosomes could be found in a cubic millimeter of blood. This scarcity of parasites continued at least to the 29th day after infection, but it is possible that some of the rats might have shown the double peak of parasitaemia described by PIZZI et al.<sup>14</sup> and confirmed by PIZZI & CHEMKE<sup>15</sup>. In any case, it would seem that the appearance in the blood of a large number of trypanosomes between the 8th and 10th day after inoculation points to the rupture of a large number of pseudocysts at this time,

The sudden decline of parasites in the blood after the 12th day of infection suggests either a dwindling of proliferative activity or a massive destruction of the parasites themselves. The increase in the blood parasites between the 4th and 8th days of infection may be attributed to the progressive release of trypanosomes formed at the site of inoculation, a phenomenon established for rats by PIZZI et al.<sup>13</sup> and in mice by TALIAFERRO & PIZZI<sup>18</sup>. In rats infected with blood forms of the "Tulahuen" strain, PIZZI et al.<sup>13</sup> observed pseudocyst in the myocardial fiber from the 6th day on, as well as leishmanoids from the 4th day on in the myocardial histiocytes and the reticular cells of the region of the ganglia. PIZZI & CHEMKE<sup>15</sup> noted the presence of leishmanoids of the same strain of *T. cruzi* in the myocardium of rats . . . "from the 9th day on, in the middle of small interstitial productive inflammatory foci, and also within the thickness of the myocardial fibers, without neighboring inflammatory reaction". TALIAFERRO & PIZZI<sup>18</sup> reported finding small numbers of the parasites in the myocardial fibers of mice, beginning from the 5th to the 7th day of infection, and increasing in number to the 9th day, when the inflammatory process began. The results reported here with the "Y" strain confirm these findings; pseudocysts were seen beginning with the 8th day of infection and it is possible that they had become established in the myocardial fibers somewhat before the 8th day, since they were not seen in the animals sacrificed on the 4th day of infection. On the 8th day, the greatest numbers of pseudocysts were seen in the right auricle, the base of the right ventricle, and the walls of the common vena cava. A similar distribution of parasites, with a predilection for the walls of the right hand cavities of the heart has been reported by KÖBERLE<sup>7</sup> in human cases, and by KLINE et al.<sup>6</sup> and KUMAR et al.<sup>9</sup> in mice infected with Colombian strains of *T. cruzi*. The relationship between the rupture of the muscular fibers by the leishmanoids and the establishment of inflammatory foci was first observed by VIANNA<sup>19</sup>. This sequence does not occur exclusively in the myocardium; TALIAFERRO & PIZZI<sup>18</sup> described it in the subcutaneous connective tissue at the site of inoculation

between the 9th and 15th day of infection, at the same time when myocardial inflammatory areas of variable intensity had appeared.

Arteritis and phlebitis are not primary processes, but appear together with the inflammatory infiltration after the rupture of the first pseudocysts, between the 10th and 11th days. The diffuse infiltration, often not spatially related to the parasites, appears not to be a reaction conditioned by circulating antibodies, but rather an immediate response to the liberation of products of parasites and of destroyed muscular fibers, possibly carried by the blood and lymph. This hypothesis appears to be supported by the observations of TALIAFERRO & PIZZI<sup>18</sup> who inoculated mice with high doses of virulent parasites 23 days after having sensitized the animals with high doses of avirulent parasites. They observed that . . . "the parasitization and the histological changes in the immune heart after the challenging dose closely paralleled those seen in the pathogenic initial infections. *The processes, however, were milder*". (italics mine).

The predominance of pseudocysts in the right chambers of the heart is almost inexplicable, unless it is assumed that the parasites arriving in the venous circulation enter the cells that they happen to strike first.

VIANNA<sup>19</sup> first recognized that parasites may be phagocytized immediately after the rupture of the myocardial pseudocysts; PIZZI & CHEMKE<sup>15</sup> noted phagocytosis of parasites in the myocardium of rats, with a following decline in the number of nests and their disappearance from the 21st day of infection. This confirms the observations of PIZZI et al.<sup>13</sup> who noted that, in the myocardium of rats . . . "the maximum parasitic destruction was observed between the 16th and 20th days" . . . and that . . . "in the heart it was seen that the infection had been dominated and that there had been no reinvasion of new myocardial fibers" . . . In our material, the parasites had disappeared from the myocardium at about the 18th day, while maximum destruction of intracardial parasites had apparently occurred about the 14th day. No reinvasion of new myocardial fibers was observed.

During the process of intense inflammation, certain of the cardiac fibers were observed to have become slender, especially in the auricles; these recovered their normal appearance when the intensity of the infiltration and the interstitial oedema diminished. The changes in the parasympathetic neurons of the subepicardial ganglia are likewise secondary to the commencement of the inflammatory process (ganglionitis and periganglionitis), being closely related with it. This is an apparently irregular process which varies within the same animal and from one animal to another. Our observations are in accord with those of ANDRADE & ANDRADE<sup>1</sup>; these Authors note the close relation between inflammation and neuronal changes of the plexus of Auerbach in the large intestine of rats infected with the "Y" strain of *T. cruzi*. They state that in one group of infected animals treated with cortisone "... the inflammatory reaction was practically abolished. The neural ganglion cells were always seen to be well preserved, well stained, without appreciable visible changes, despite the presence of leishmanias in their vicinity". The findings of TAFURI<sup>17</sup> were similar; he reported that, in mice infected with various strains of *T. cruzi*, the neuronal lesions of the plexi of Meissner and Auerbach, as well as of the coeliac, lumbar, and subepicardial ganglia were always observed to be related to the inflammatory process, whose irregular distribution would explain the irregularity of occurrence of the neuronal changes.

The cardiac changes observed in our animals following the 25th day of infection consisted of a marked decrease of the inflammatory process and of vasculitis. At 29 days there were observed scanty lymphomonocytic foci and discrete foci of fibrosis of the auricles and the bases of the ventricles. The neural changes persist giving the impression of being reduced in number. Certain subepicardial ganglia showed various degrees of fibrosis.

#### RESUMÉN

*Miocarditis aguda en ratas inoculadas con Trypanosoma cruzi: Estudio de animales sacrificados entre el cuarto y vigésimo noveno día después de la inoculación.*

Se describen las lesiones miocárdicas agudas observadas en 56 ratas Wistar hembras de 40 días inoculadas con formas sanguíneas de *Trypanosoma cruzi*, cepa Y. Se ha observado el curso de la parasitemia en algunos animales comparándola con las alteraciones microscópicas del miocardio de animales similares. El estudio del material a diferentes períodos después de la inoculación revela la semejanza existente entre las lesiones encontradas y lesiones humanas o de material experimental investigado por otros Autores, destacándose procesos de ganglionitis y periganglionitis de los ganglios parasimpáticos subepicárdicos con destrucción irreversible de grupos de neuronas. Se discute la relación entre estas alteraciones y la intensidad del proceso inflamatorio agudo.

#### ACKNOWLEDGMENTS

The Authors express their gratitude to Professor A. G. E. Pearce from the Royal Postgraduate Medical School (London) for his advice during the realization of this work and for providing facilities to do it. To Mr. Ian McLure for translating the original Spanish into English. This work was supported by a fellowship from the Council for Scientific Development of the Central University in Caracas, Venezuela.

#### REFERENCES

1. ANDRADE, S. G. & ANDRADE, Z. A. — Doença de Chagas e alterações neuronais no plexo de Auerbach. *Rev. Inst. Med. trop. São Paulo* 8:219-224, 1966.
2. BANCROFT, J. — *An Introduction to Histochemical Technique*. London, Butterworths, 1967.
3. BRENER, Z. — *Contribuição ao estudo da terapêutica experimental da doença de Chagas*. Tesis. Belo Horizonte, 1961.
4. DIAS, E. — Estudios sobre o *Schizotrypanum cruzi*. *Mem. Inst. Oswaldo Cruz* 28:1-10, 1934.
5. GOMEZ DE ALCANTARA, F. — Experimentelle Chagaskardiomyopathie. *Zts. Tropenmed. Parasit.* 10:296-303, 1959.
6. KLINE, I. K.; KUMAR, R. & ABELMANN, W. H. — Right ventricular involvement in

SCORZA, C. & SCORZA, J. V. — Acute myocarditis in rats inoculated with *Trypanosoma cruzi*: Study of animals sacrificed between the fourth and twenty-ninth day after infection. *Rev. Inst. Med. trop. São Paulo* 14:171-177, 1972.

- experimental Chagas' myocarditis. *Amer. J. Clin. Path.* 50:599, 1968.
7. KÖBERLE, F. — Cardiopatia Chagásica. *Hospital (Rio)* 53:9-50, 1958.
  8. KOLODNY, M. H. — Studies on age resistance against trypanosome infections. VII — The influence of age upon the immunological response of rats to infection with *Trypanosoma cruzi*. *Amer. J. Hyg. (Sect. C)* 31:1-8, 1940.
  9. KUMAR, R.; KLINE, I. K. & ABELMANN, W. H. — Experimental *Trypanosoma cruzi* myocarditis. *Amer. J. Path.* 57:31-48, 1968.
  10. LILLIE, R. D. — *Histopathologie Technic and Practical Histochemistry*. New York, The BlaKiston Comp. Inc., 1954.
  11. LISON, L. & DAGUELIE, J. — *Bull. Histol. Appl.* 12:85, 1935 (cited by BANCROFT, J. 1967) in *An Introduction to Histochemical Technique*. London, Butterworths.
  12. PEARSE, A. G. E. — *Histochemistry, Theoretical and Applied*. Vol. 1. Third Edition. London, J. & A. Churchill Ltd., 1968.
  13. PIZZI, T.; RUBIO, M. & KNIERIM, F. — Contribución al conocimiento de los mecanismos inmunitarios en la enfermedad de Chagas experimental de la rata. *Bol. Inf. Parasit. Chil.* 8:66-72, 1953.
  14. PIZZI, T.; RUBIO, M.; PRAGER, R. & SILVA, C. — Acción de la cortisona sobre la infección experimental por *Trypanosoma cruzi*. *Bol. Inf. Parasit. Chil.* 7:22-24, 1952.
  15. PIZZI, T. & CHEMKE, S. — Acción de la cortisona sobre la infección experimental de la rata por *Trypanosoma cruzi*. *Biológica* 21:31-58, 1955.
  16. SILVA, L. H. P. da & NUSSENZWEIG, V. — Sobre uma cepa de *Trypanosoma cruzi* altamente virulenta para o camundongo branco. *Fol. Clin. Biol.* 20:191-207, 1953.
  17. TAFURI, W. L. — Lesões do sistema nervoso autônomo do coração e do colon do camundongo na fase aguda da Doença de Chagas experimental. Estudos ao microscópio ótico e ao eletrônico. *Rev. Assoc. Med. Minas Gerais* 19:3-39, 1968.
  18. TALIAFERRO, W. H. & PIZZI, T. — Connective tissue reactions in normal and immunized mice to a reticulotropic strain of *Trypanosoma cruzi*. *J. Infect. Dis.* 96:199-226, 1955.
  19. VIANNA, G. — Contribuição para o estudo da anatomia patológica da moléstia de Carlos Chagas. *Mem. Inst. Oswaldo Cruz* 3: 276-293, 1911.
  20. VICHI, L. — Destruição de neuronios motores na medula espinal de ratos na fase aguda da moléstia de Chagas. *Rev. Inst. Med. trop. São Paulo* 6:150-154, 1964a.
  21. VICHI, L. — Avaliação quantitativa do parasitismo no coração, vasos da base e coronária do rato, na fase aguda da moléstia de Chagas. *Rev. Inst. Med. trop. São Paulo* 6:292-296, 1964b.

Recebido para publicação em 5/10/1971.